

Retrospective analysis of long-term (up to 12 years) clinical and radiological performance of Brånemark System TiUnite surface implants

Fabrizia Luongo¹, Antonio Cipressa², Giuseppe Luongo³

¹Private practice, Rome, Italy; ²Private practice, Perugia, Italy; ³University Federico II Naples, Naples, Italy

Topic: Implant therapy outcomes, peri-implant biology aspects

Background

Limited data are available on the long-term clinical and radiological performance of moderately rough surface implants.¹⁻³

Aim

The main objective of this study was to evaluate long-term implant survival, marginal bone levels, as well as bone remodeling around anodized surface implants (TiUnite, Nobel Biocare AB, Göteborg, Sweden) after up to 12 years of function.

Material and Methods

- In this retrospective study, the charts of patients who had received implants between years 2000 and 2011 were reviewed.
- Data from patients who had received at least one Brånemark System (Mk III or Mk IV) implant with a TiUnite surface were selected, de-identified, and used for statistical analysis.
- The implant survival rate was calculated on implant- and patient-level.
- In addition, implant stability, probing pocket depth, and plaque presence were assessed.
- De-identified radiographs were analyzed by an independent radiologist in Gothenburg (Sweden). For statistical analysis, the radiographs were clustered into time intervals.
- The marginal bone remodeling was calculated for paired radiographs. Radiographs taken at implant insertion were used as a baseline for bone remodeling calculations.
- For each implant, two marginal bone level values were recorded: one at insertion, and one at last follow-up. Thus 4 follow-up cohorts were established: baseline to 4-6 years, baseline to 6-8 years, baseline to 8-10 years, and baseline to 10-13 years of follow-up.
- Descriptive statistics were used to evaluate bone remodeling for each cohort.

Figure 1: Study implants: Brånemark System Mk III (left panel) and Mk IV (right panel) implant with anodized surface.



Results

- Overall, data for 195 Brånemark System implants with anodized surface (96.4% Mk III, 3.6% Mk IV) placed in 60 patients were included in the analysis. The mean follow-up period was 7.6 years (range 0.6–12.1 years).
- 33.3% of the implants were used for single tooth restorations, 60% were used for partial restorations, and 6.7% were used for full arch restorations.
- Implants were placed in either a one-stage (n=16) or a two-stage (n=179) surgical procedure.
- 12 implants were loaded immediately and the remaining 183 implants were loaded after a healing phase of 3-6 months.
- The implant survival rate after up to 12 years of function was 99.0% on implant level and 96.7% on patient level.
- Implant stability was excellent in 99.5% of the cases.
- As of last follow-up, no plaque was present at 66 implants (33.8%).
- The mean marginal bone remodeling remained low for all time intervals (Table 1).

Table 1: Marginal bone remodeling.

	Cohort 1 (Baseline to 4-6 years follow-up)		Cohort 2 (Baseline to 6-8 years follow-up)		Cohort 3 (Baseline to 8-10 years follow-up)		Cohort 4 (Baseline to 10-13 years follow-up)	
Mean	0.26		-0.41		-0.33		-1.28	
Median	-0.05		-0.32		-0.23		-0.50	
S.D.	1.38		0.74		1.22		2.23	
n	12		12		47		37	
Maximum	3.69		0.51		2.66		1.32	
Minimum	-1.35		-2.18		-2.74		-8.22	
	n	%	n	%	n	%	n	%
> 3.0	1	8.3	-	-	2	-	-	-
2.1 - 3.0	-	-	-	-	2	4.3	-	-
1.1 - 2.0	1	8.3	-	-	2	4.3	3	8.1
0.1 - 1.0	4	33.3	3	25	14	29.8	8	21.6
0	-	-	-	-	2	4.3	1	2.7
-1.0 - -0.1	5	41.7	7	58.3	16	34.0	9	24.3
-2.0 - -1.1	1	8.3	1	8.3	5	10.6	5	13.5
-3.0 - -2.1	-	-	1	8.3	6	12.8	7	18.9
-4.0 - -3.1	-	-	-	-	-	-	1	2.7
-5.0 - -4.1	-	-	-	-	-	-	-	-
-6.0 - -5.1	-	-	-	-	-	-	1	2.7
-7.0 - -6.1	-	-	-	-	-	-	1	2.7
< -8.0	-	-	-	-	-	-	1	2.7
Total	12	100	12	100	47	100	37	100

Clinical Case

A 51 year old male patient presented with a traumatic fracture of his upper lateral incisor (position 12). The tooth was carefully extracted and a Brånemark System TiUnite MKIII RP 3.75 x 13 mm implant was inserted. The implant was immediately loaded with a temporary crown. The final crown was inserted 3 months later. The patient has since been followed every 6 months for 12 years. The last results (at age 63) show perfect integration and no marginal bone loss.

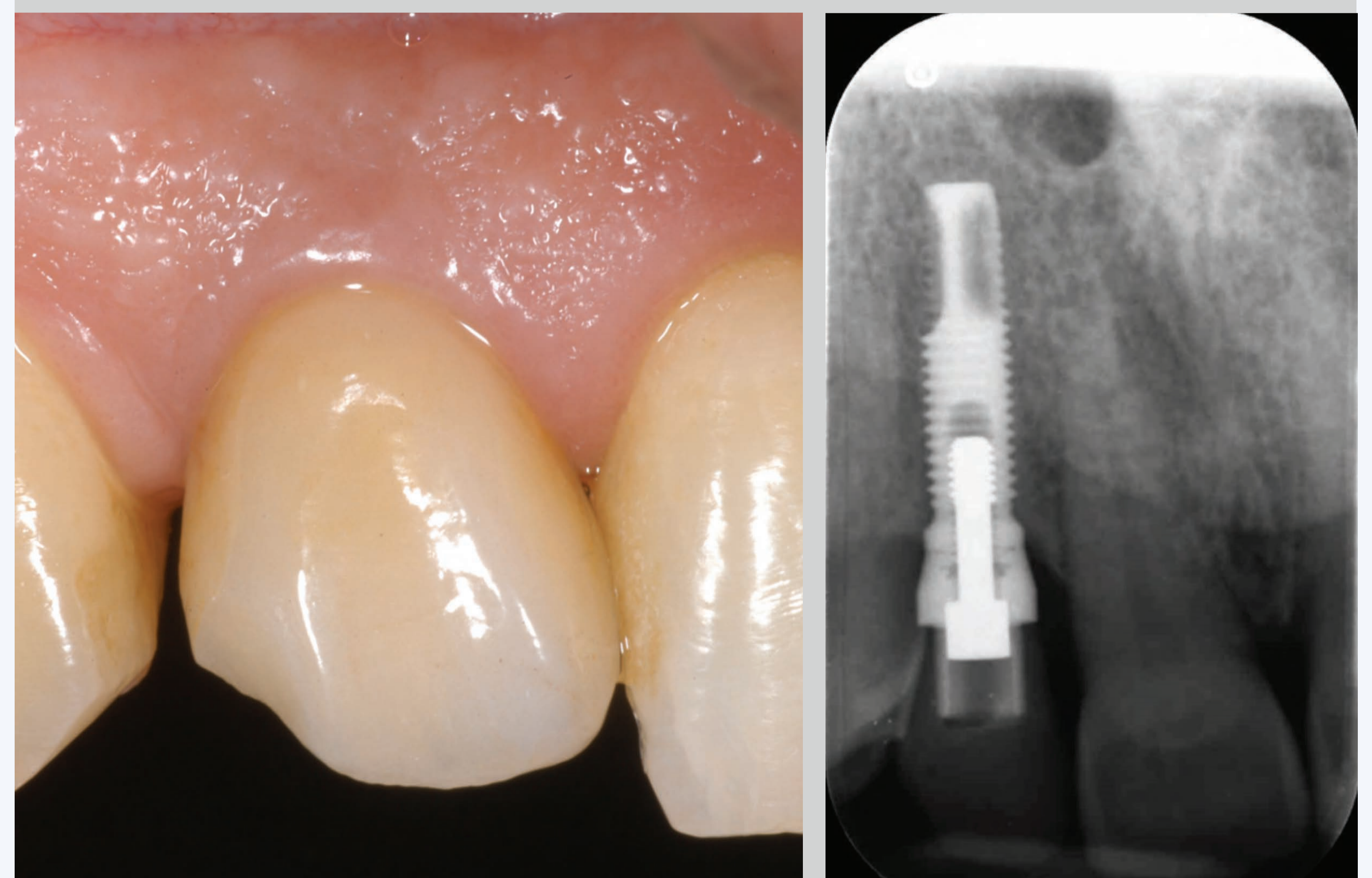
Figure 2: Traumatic fracture of tooth 12. Labial view (left) and fractured tooth after extraction (right).

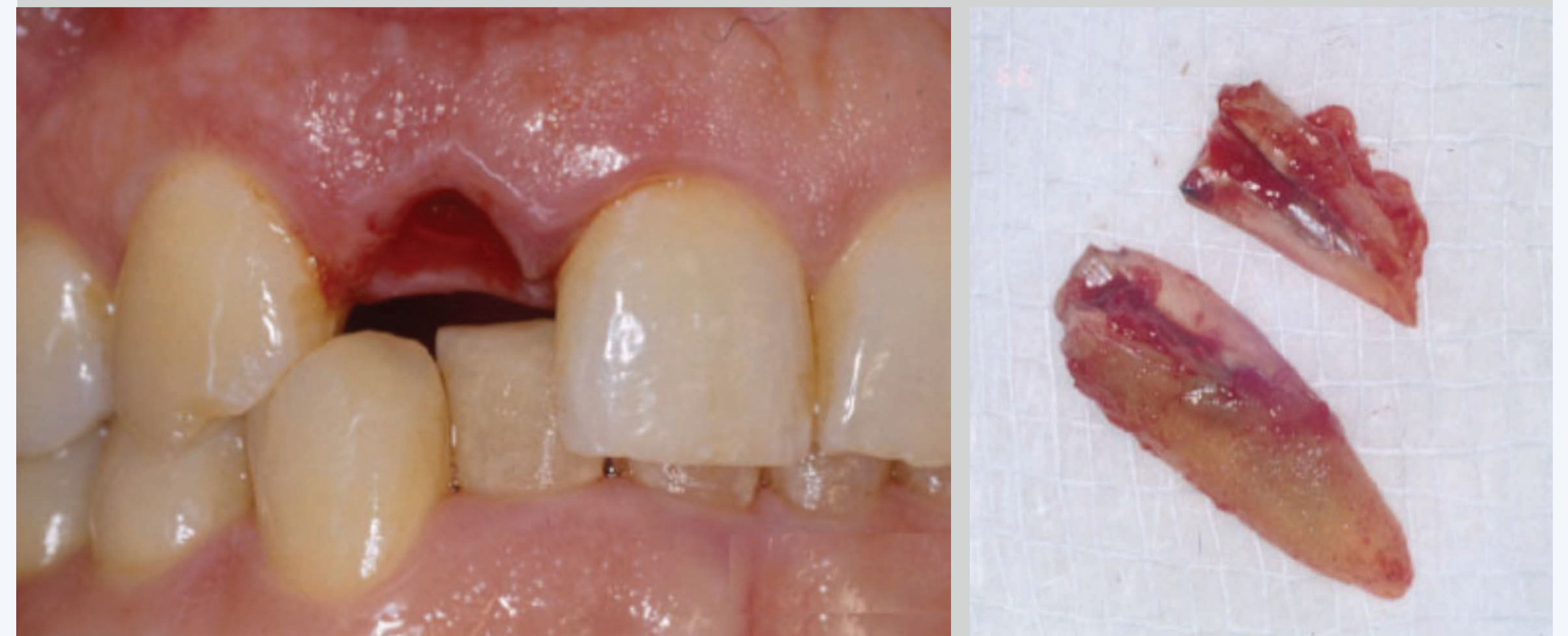

Figure 2: Post-extractive implant insertion (left) and immediate delivery of the temporary prosthesis (right).

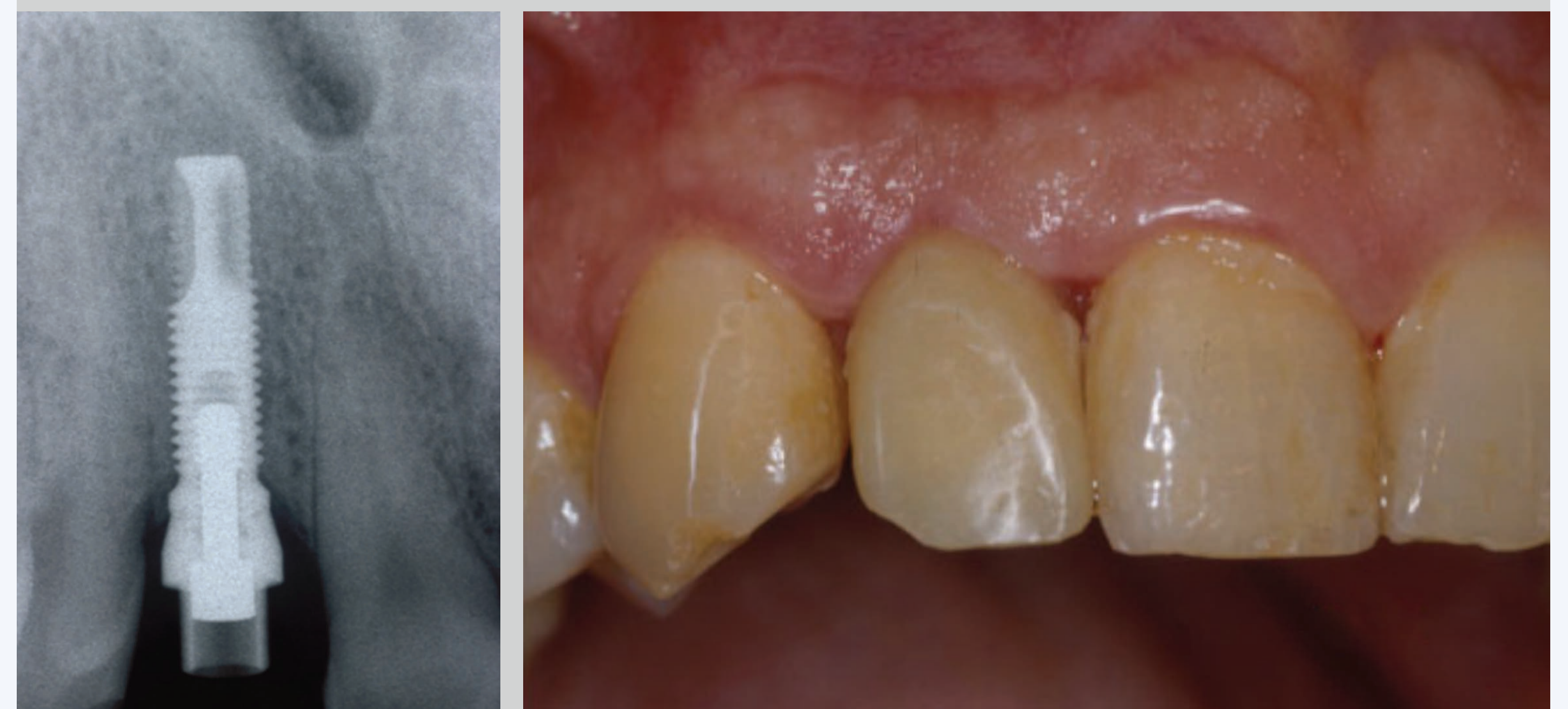

Figure 3: Final prosthesis delivery 3 months after implant placement (left) and radiograph at 12 years after implant placement (right). Note the perfect integration and no marginal bone loss.



Conclusions

The results from this long-term retrospective investigation show that Brånemark System implants with TiUnite surface are a safe and reliable option with high implant survival rates and low bone remodeling.

References

- Glaser R. Implants with an Oxidized Surface Placed Predominately in Soft Bone Quality and Subjected to Immediate Occlusal Loading: Results from an 11-Year Clinical Follow-Up. *Clin Implant Dent Relat Res.* epub ahead 2015.
- Mozzati M, Galesio G, Del Fabbro M. Long-term (9-12 years) outcomes of titanium implants with an oxidized surface: a retrospective investigation on 209 implants. *Journal of Oral Implantology.* 2015;41(4):437-43.
- Zou D, Huang W, Wang F, Wang S, Zhang Z, Zhang C, et al. Autologous Ilium Grafts: Long-Term Results on Immediate or Staged Functional Rehabilitation of Mandibular Segmental Defects Using Dental Implants after Tumor Resection. *Clin Implant Dent Relat Res.* 2015;17(4):779-89.

This study has been partially supported by Nobel Biocare (grant 2012-1084)

